

Pediatric Urology

**EXPRESSION OF VARIOUS CELLULAR MARKERS IN GENITOURINARY RHABDOMYOSARCOMA:
IMMUNOHISTOCHEMICAL STUDY USING TMA METHODOLOGY**

Pinthus JH et al.

PURPOSE: Immunohistochemical analysis of the expression of various cellular markers in rhabdomyosarcoma (RMS) may improve the design of therapeutic schedules according to individualized risk-based data and may even define specific therapeutic targets in RMS. The aim of this study was to evaluate the extent of the expression of various cellular markers in RMS, using tissue microarray (TMA) technique.

MATERIAL AND METHODS: TMA paraffin embedded block was constructed of 8 samples of RMS from different patients. Each tumour sample was presented in the block by several cores, 2 mm in diameter, containing tumour tissue with adjacent transitional epithelium and normal detrusor which served as positive and negative controls. After serial slicing of 4 µm thickness, the histological slides were stained with hematoxylin & eosin (H&E) and immunostained with antibodies against Erb-B2, p53, c-kit, Ki 67, Caspase 3, EGFR, N-CAM, TOPO-II and BCL-10. The immunostaining was graded semi quantitatively by the percent of positively staining cells and the intensity of stain.

RESULTS; Four cellular markers were expressed in RMS including Erb-B2, Ki 67, EGFR and N-CAM. Significant positive staining (grades 2-3), for at least one of these markers, was noted in 5 of the cases.

CONCLUSIONS: The expression of Erb-B2, Ki 67, EGFR and N-CAM in genitourinary RMS may have potential therapeutic implications. Our preliminary results may promote further studies to assess the potential role of these markers to serve as therapeutic targets for specific therapeutic agents and thus decrease the overall treatment burden in children suffering from genitourinary RMS.

TESTICULAR FIXATION FOLLOWING TORSION OF THE SPERMATIC CORD: DOES IT GUARANTEE PREVENTION OF RECURRENT TORSION EVENTS?

Mor Y, Pinthus JH, Nadu A, Golomb J, Ramon J

PURPOSE: Patients with history of testicular torsion who have undergone orchiopexy may rarely present with acute scrotum due to recurrent episodes of torsion. Most of the reports in the literature regarding this scenario refer to the era when absorbable sutures were used for testicular fixation. Herein, we review our experience in recent years, focusing upon the surgical technique and sutures' material.

MATERIALS AND METHODS: Between 1991 and 2003, 179 patients were operated on at our institute with the clinical diagnosis of unilateral testicular torsion. They ranged in age between neonates to 45 years old (average age 18). In a comprehensive retrospective study we managed to locate 8 patients who experienced recurrent intravaginal testicular torsion following previous fixation performed in our institute.

RESULTS: The patients who experienced repeat torsion have initially presented at the mean age of 18.5 years old (range 12 to 30) with unilateral twisted testicle (left 3, right 5). Urgent explorations were generally performed, apart from in 2 cases that underwent spontaneous detorsion which was followed by an elective surgery. Testicular fixation was conducted by suturing of the tunica albuginea to the dartos layer by 2 sutures at each side, using chromic 3-zero in the 3 more early cases, followed by the usage of polyglactin 3-zero stitches in 4 subsequent cases and 3 sutures of polypropylene 4-zero for each testicle, thereafter, in the most recent case. The patients presented with repeat torsion, 0.5 to 23 years subsequently (average 7 years), involving either the ipsilateral testicle in 4 cases or the contralateral gonad in 4.

CONCLUSIONS: Recurrent torsion following previous testicular fixation may appear many years following the primary procedure, even in cases in which either polyglactin or, notwithstanding, polypropylene sutures have been applied, in accordance with the common practice used in the last 2 decades. Increased awareness regarding this possibility is imperative for early diagnosis and prevention of testicular loss.

OUTCOMES AND QUALITY OF LIFE OF ADULTS UNDERGOING CONTINENT CATHETERIZABLE VESICOSTOMY FOR NEUROGENIC BLADDER

Touma N, Horovitz D, Shetty A, Caumartin Y, DeMaria J, Luke P

OBJECTIVES: To evaluate the functional outcomes and quality of life of adult patients with neurogenic bladders who had undergone Casale Spiral Monti vesicostomy.

METHODS: Twelve patients who underwent Casale Spiral Monti vesicostomy from May 1999 to December 2004 were evaluated with the Medical Outcomes Study 36-item short-form health survey to assess for postoperative quality of life. Complications and patient reported continence were also documented.

RESULTS: The 12 patients (mean age 27.4 years) were followed up for a mean of 2.8 years. All 12 reported excellent urinary continence after the procedure, with only 7 patients who had the capacity to self-catheterize. Two patients reported wearing one light pad per day over the stoma. Two patients required one endoscopic dilation each for stomal stenosis, and one patient was readmitted 3 weeks postoperatively for the management of paralytic ileus. Eight patients reported no urinary tract infection since the operation. All 12 patients reported being very satisfied with the procedure.

CONCLUSIONS: The results of this study have demonstrated that Casale Spiral Monti vesicostomy can have dramatic positive effects on the quality of life in adults with a neurogenic bladder by granting them social independence, convenient bladder management, and excellent continence rates.

CORPORAL SPARING DISMEMBERED CLITOROPLASTY: AN ALTERNATIVE TECHNIQUE FOR FEMINIZING GENITOPLASTY

Braga LH

PURPOSE: Management for clitoral enlargement remains controversial. New understanding of clitoral function stimulated a search for more conservative surgical approaches, such as recession or partial resection. However, these techniques risk decreasing clitoral sensation or causing painful erections. Moreover, irreversibility continues to be the principal problem that fuels patient, surgeon and societal anxiety in the management of this challenging developmental issue. We describe a new technique, corporeal sparing dismembered clitoroplasty, that dismembers the corporeal bodies and preserves all clitoral structures.

MATERIALS AND METHODS: After obtaining full informed consent and institutional review board approval 8 consecutive patients with clitoral enlargement underwent corporeal sparing dismembered clitoroplasty. Five girls had congenital adrenal hyperplasia (Prader IV and V in 4 and 1, respectively), 1 had ovotesticular disorder of sexual differentiation and 2 had partial androgen insensitivity syndrome. One pubertal girl was tested with warm, cold and pain clitoral stimulation before and after surgery. For the clitoroplasty technique the glans and its neurovascular bundles are dissected from the corpora. The isolated corpus is then completely divided starting at the bifurcation. Each separated hemicorpus is rotated inferior and lateral, to be placed inside the labial scrotal folds. The glans is reduced by superficial excision of its epithelium and fixed to the pubic attachments. Labia minora are constructed with preputial Byars flaps. Labioplasty and vaginoplasty are then routinely performed.

RESULTS: Eight patients 6 months to 13 years old underwent this procedure. Followup was 6 to 12 months. All patients recovered well from surgery without early complications. The initial cosmetic result was good in all girls. The hemicorpora were easily palpated inside their labia majora pouches, which retained the desired cosmetic appearance following feminizing genitoplasty. All glans clitoris were preserved. The teenaged patient does not report painful erections. She has maintained clitoral sensation and is satisfied with the cosmetic result.

CONCLUSIONS: Conservative reconfiguration of the female genitalia without removing genital structures is feasible in girls with clitoral enlargement. The cosmetic appearance of the genitalia is acceptable, at least to the surgeon and parents, in that the enlarged clitoris is hidden. The physiological consequences of the current operation and any surgery in the future to reverse it are unknown. With these aspects in mind we believe that corporeal sparing dismembered clitoroplasty should be incorporated into the armamentarium of surgeons involved in the treatment of clitoral enlargement and presented as an option for feminizing genitoplasty.

COMPARATIVE ANALYSIS OF TIP VERSUS ONLAY URETHROPLASTIES FOR PENOSCROTAL HYPOSPADIAS

Braga LH

PURPOSE: Despite being the dominant technique for repair of distal hypospadias, application of the tubularized incised plate approach for penoscrotal hypospadias remains controversial. We report our experience with severe hypospadias, comparing tubularized incised plate to transverse island flap onlay urethroplasty.

MATERIALS AND METHODS: We retrospectively reviewed consecutive patients with penoscrotal hypospadias presenting between 1998 and 2006. Based on surgeon preference 35 children underwent tubularized incised plate and 40 underwent onlay urethroplasty. Penoscrotal transposition and degree of ventral curvature, type of ventral curvature repair, complication rate, postoperative uroflowmetry pattern in toilet trained patients and number of reoperations were compared between the 2 groups.

RESULTS: Mean patient age at surgery was 17 months (range 9 to 91) for tubularized incised plate urethroplasty and 17.8 months (10 to 58) for the onlay procedure. Urethroplasty was performed over an 8Fr catheter in all patients. With mean followups of 30 months (range 6 to 74) and 38.8 months (16 to 80) the overall complication rates were 60% and 45% for the tubularized incised plate and onlay procedures, respectively. Fistula occurred in 15 patients and repair breakdown in 3 patients (total 51.4%) treated with tubularized incised plate repair, compared to 8 and 2 patients, respectively (25%), treated with onlay repair ($p = 0.01$). Fistula location also differed significantly between the 2 groups, with proximal fistulas occurring in 11 of 15 tubularized incised plate repairs (73.3%) vs 2 of 8 onlay repairs (25%, $p = 0.02$). Recurrent ventral curvature was more frequent after onlay urethroplasty (5.7% vs 12.5%, not significant). At a mean age of 5.1 years a plateau uroflow curve (vs normal bell curve) was observed in 16 of 24 children (66.7%) who underwent tubularized incised plate repair and in 7 of 21 (33.3%) who underwent onlay repair ($p < 0.01$).

CONCLUSIONS: In this series the overall complication rate was similar for tubularized incised plate and onlay urethroplasty. Despite similar urethroplasty calibers, the uroflow curves and fistula positions in patients undergoing tubularized incised plate repair suggest that the neourethra distal to the fistula may be relatively narrow, creating flow resistance and leading to proximal fistula. Longer followup and close monitoring are needed before embracing one approach over the other.

GENDER-BASED OUTCOME ANALYSIS AFTER COMPLETE PRIMARY REPAIR OF BLADDER EXSTROPHY (CPRE)

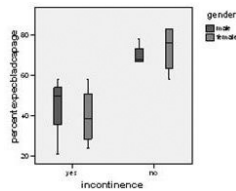
Braga LH, Lorenzo AJ, Jreaz R, Bagli DJ, Farhat WA, Pippi Salle JL, Khoury AE

INTRODUCTION AND OBJECTIVE: CPRE may result in improved bladder capacity (BC) due to early creation of bladder outlet resistance. In addition, reports suggest that females have better urinary continence and decreased need for bladder neck reconstruction after CPRE relative to males. We present an outcome analysis for CPRE, looking at gender related differences.

METHODS: We conducted a retrospective chart review of 27 consecutive babies who underwent CPRE between 1997-2007. One pt died due to cardiac anomaly and was excluded. The following variables were analyzed separately by gender: complications, need for bladder neck reconstruction (BNR) or endoscopic injection (EI), clean intermittent catheterization (CIC), bladder augmentation, and post-operative hydronephrosis (HN), vesicoureteral reflux (VUR), urinary tract infection (UTI), urinary continence (dry interval >4h), and percent of expected BC for age (PEBCA).

RESULTS: Median age at surgery was 3 days (1-140). 13 males and 13 females were studied. Mean follow-up (FU) was 61.6m (17-105) for boys and 54.2m (11-97) for girls ($p=0.67$). Bilateral oblique innominate osteotomies were performed in 22 pts. Complications included: In boys -recurrent dorsal curvature (2- one pt also had fistula), fistula (1) and hemi-glans ischemia (1), in girls -bladder dehiscence (1), urethral mucosa prolapse (1) and bladder stone (1). Three males and 4 females underwent BNR+CIC; 4/7 had previous unsuccessful EI. BA was performed in 2 girls. Mean age at last FU was $72 \pm 42m$ for boys and $63 \pm 41m$ for girls ($p=0.58$). Five of 6 (83%) males and 5 of 8 (62%) females have at least 2-4h dry intervals after CPRE. Four girls are dry >4h after 1 procedure vs. no boys ($p=0.05$). One boy and 4 girls had simultaneously bilateral ureteral reimplantation at the time of CPRE. Postop febrile UTI was seen in 3/13 boys vs. 8/13 girls. Two boys and 6 girls developed HN after CPRE. Correlation between PEBCA and urinary incontinence adjusting for gender is shown in the figure.

CONCLUSIONS: PEBCA is a good indicator of continence status in both genders. Our data suggest that males and females have comparable urinary continence rates when 2-4h dry intervals are considered. However, once dryness >4h is contemplated, continence after a single procedure (CPRE) is better in girls than boys.



TOTAL UROGENITAL SINUS MOBILIZATION IN THE REPAIR OF AMBIGUOUS GENITALIA IN CHILDREN WITH CONGENITAL ADRENAL HYPERPLASIA

Braga LH, Silva IN, Tatsuo ES.

ABSTRACT: The surgical approach to patients with congenital adrenal hyperplasia (CAH) has been a challenge and it is still controversial. The aim of this study was to review 10 children with 46,XX CAH who underwent one-stage total urogenital sinus mobilization (TUM). Age at operation ranged from 11 to 78 months (mean= 32) and the follow-up from 15 to 36 months (mean= 26). Cosmetic results were good in 7 patients and satisfactory in 3. After a mean follow-up of 26 months, our results showed that TUM was a good option to repair ambiguous genitalia in children with CAH.

PEDIATRIC LAPAROSCOPIC PYELOPLASTY IN A REFERRAL CENTER: LESSONS LEARNED

Braga LH, Pippi Salle JL, Lorenzo AJ, Bagli DJ, Khoury AE, Farhat WA

PURPOSE: We present our first-year experience with pediatric transperitoneal laparoscopic dismembered pyeloplasty (TLDP) in a large referral center.

PATIENTS AND METHODS: A chart review was conducted in 27 consecutive children (M:F 23:4) aged 4 to 17 years (mean 9.7 years) with ureteropelvic junction obstruction who underwent TLDP (21 on the left, 6 on the right) in 2005. The key steps implemented to facilitate and streamline this procedure were: (1) clamping the Foley catheter before surgery to distend the renal pelvis and facilitate the transmesenteric approach; (2) stabilizing the renal pelvis with a traction suture; (3) performing the dismembered pyeloplasty using a modified double-armed suture; and (4) placing the ureteral stent percutaneously antegrade before completing the anastomosis. Operative time, hospital stay, complications, and follow-up radiologic studies were reviewed.

RESULTS: The TLDP was performed with no open conversions. Crossing vessels and horseshoe kidney were present in 8 patients and 2 patients, respectively. The mean operative time was 221 minutes. Stent insertion was successful in all but one patient. Postoperative pain management was successful in all 27 patients. There were 4 postoperative complications (14.8%) consisting of prolonged leakage in two, obstruction in one, and obstruction with pyelonephritis in one. These last two complications occurred early in our experience and were treated successfully by percutaneous nephrostomy with subsequent retrograde endopyelotomy. The average hospital stay was 2.1 days (range 1-4 days). Radiologic studies 8 to 20 months after removal of the Double-J stents showed reduction of the degree of hydronephrosis in all patients.

CONCLUSION: Our 1-year experience with TLDP gave us the opportunity to implement key steps to establish a standardized technique for this procedure. Although the follow-up period was short, most complications occurred early in this series, demonstrating that a learning curve is inevitable.

OUTCOME ANALYSIS OF SEVERE CHORDEE CORRECTION USING TUNICA VAGINALIS AS A FLAP IN BOYS WITH PROXIMAL HYPOSPADIAS

Braga LH, Pippi Salle JL, Dave S, Bagli DJ, Lorenzo AJ, Khoury AE

PURPOSE: There is ongoing controversy regarding optimal treatment for severe ventral curvature. It has been suggested that ventral corporeal lengthening may be associated with recurrent curvature and erectile dysfunction. To further assess these issues we reviewed our experience with ventral penile lengthening for correcting the severe ventral curvature associated with proximal hypospadias.

MATERIALS AND METHODS: We reviewed the records of 38 boys with severe hypospadias and congenital ventral curvature greater than 45 degrees who were treated at our institution from 1995 to 2004 with placement of a flap or graft in the corporeal bodies to straighten the phallus. Of the patients 21 had perineal and 17 had penoscrotal hypospadias, including 22 with associated penoscrotal transposition and/or bifid scrotum and 6 with ambiguous genitalia. Testosterone stimulation before surgery was given in 11 children at surgeon discretion.

RESULTS: Median age at surgery was 15 months. The urethral plate was divided in 94.7% of patients. A tunica vaginalis flap was used alone in 23 cases and associated with dura, pericardium or small intestinal submucosa in 8, 2 and 1, respectively. The remaining 4 patients underwent ventral grafting alone, including lyophilized dura in 1, pericardium in 1 and dermis in 1. Urethral reconstruction was achieved by the transverse island flap technique or 1 of its modifications in 34 children. Four boys underwent a 2-stage procedure. Followup available on 35 of 38 patients was 1 to 11 years (median 5.3). Recurrent ventral curvature in 5 of 35 patients was mild in 1 and clinically significant, requiring re-intervention, in 4. Four of 9 patients (44.4%) who underwent corporeal grafting with lyophilized dura had recurrent ventral curvature vs 1 of 23 (4.3%) who had a tunica vaginalis flap (chi-square 5.14, $p = 0.02$). At last followup straight erections were documented by patients and/or parents in 30 of 35 children (85.7%).

CONCLUSIONS: The short-term outcome of ventral penile lengthening using tunica vaginalis flap alone for correcting severe chordee is favorable with a 95% success rate. Dural grafts were associated with a higher risk of recurrent ventral curvature compared to tunica vaginalis flaps. Although most of our patients were not yet adults, when chordee and erectile dysfunction may become apparent, we believe that tunica vaginalis flap repair is a good option for correcting severe ventral curvature.

LONG-TERM RENAL FUNCTION AND CONTINENCE STATUS IN PATIENTS WITH CLOACAL MALFORMATION

Braga LH, Lorenzo AJ, Dave S, Del-Valle MA, Khoury AE, Pippi Salle JL

INTRODUCTION: Urinary continence after cloacal repair is difficult to achieve and renal outcome in patients with cloacal malformations has been scarcely reported. As a result, we reviewed our experience with cloacal malformations to determine the status of continence and the long-term renal function in these children.

METHODS: A retrospective chart review from 1990 to 2003 identified 12 patients with cloacal malformation (1 posterior, 4 complex and 7 classical) who underwent surgical reconstruction. The confluence was defined as high (common channel ≥ 3 cm) and low (< 3 cm) by cystovaginoscopy. Renal ultrasound, voiding cystourethrogram, renal scan and sacral radiograph were performed in all children. Most patients underwent 1-stage abdominoperineal pull-through, applying the principle of total urogenital sinus mobilization. We collected data regarding hydronephrosis, vesicoureteral reflux and split differential renal function. Renal outcome was evaluated based on glomerular filtration rate and ageadjusted serum creatinine values ($\mu\text{mol/L}$). Urinary continence was defined as a dry interval > 4 hours.

RESULTS: Patients' mean age at surgery was 20 months (range 7–29 mo). Of the 12 children who underwent cloacal repair, 7 (58.3%) had a common channel ≥ 3 cm. Renal anomalies were identified in 3 of 12 (25%) girls: there were 2 solitary kidneys and 1 pelvic kidney. Lumbar–sacral radiography demonstrated bony abnormalities in 11 of the 12 (91.6%) cases: hemivertebra in 3 cases, sacral agenesis in 4 cases, hypoplastic sacrum in 3 cases and bifid sacrum in 1 case. Total urogenital sinus mobilization through an abdominoperineal approach in a single stage was performed in 8 girls. Follow-up ranged from 4 to 14 years (mean 8.5 yr). Eight (66.6%) children had dry intervals > 4 hours, 5 (62.5%) of them were on clean intermittent catheterization through a Mitrofanoff channel and 1 (12.5%) was through the urethra. The remaining 2 (25%) patients were voiding spontaneously. Three (33.3%) patients were totally incontinent, and 1 (8.3%) patient was awaiting reconstruction. The mean measured glomerular filtration rate was $93.5 \text{ L/min/1.73m}^2$ (range 34–152 L/min/1.73m^2). Four (57.1%) of 7 patients who had a common channel ≥ 3 cm ended up needing augmentation cystoplasty, compared with none of the patients with a common channel < 3 cm (57.1% v. 0%, $p = 0.038$).

CONCLUSION: Urinary continence can be achieved in most patients with cloacal malformation at the expense of major reconstructive surgery and despite the presence of associated urological abnormalities. However, these children harbour an important risk for renal impairment later in life and should be closely monitored.

SEVERE BLADDER TRABECULATION OBIATES THE NEED FOR BLADDER OUTLET PROCEDURES DURING AUGMENTATION CYSTOPLASTY IN INCONTINENT PATIENTS WITH NEUROGENIC BLADDER

Khoury AE, Dave S, Peralta-Del Valle MH, Braga LH, Lorenzo AJ, Bägli D

OBJECTIVE: To evaluate whether the degree of preoperative bladder trabeculation in neurogenic bladder (NB) patients is a marker of significant outlet resistance. If so, severe trabeculation may obviate the need for concomitant bladder outlet procedure (BOP) during augmentation cystoplasty (AC).

PATIENTS AND METHODS: We retrospectively reviewed 48 incontinent patients with NB who had surgery. The patients were divided into two groups: group 1 (23 patients) had AC alone; group 2 (10) had AC with BOP. Children who had a BOP alone (15) were excluded from the study. Success was defined as a dry period of $>$ or $=$ 4 h. Preoperative bladder trabeculation was classified as mild or severe. Data collected included continence status, imaging and urodynamic findings.

RESULTS: In group 1 patients before surgery, there was severe bladder trabeculation in 14 (61%), hydronephrosis in 13 (57%) and associated vesico-ureteric reflux (VUR) in 16 (70%). The mean detrusor leak-point pressure (DLPP) was 49.7 cmH₂O and the bladder neck was open in nine (39%). Dryness with AC alone was achieved in 91% of group 1 patients. In group 2 patients (10 patients), there was severe bladder trabeculation in five, hydronephrosis in three, and VUR in two. The mean DLPP was 42.8 cmH₂O and the bladder neck was open in eight. After surgery, eight of 10 patients achieved a dry period of 4 h. There was no significant difference between group 1 and 2 patients for age at surgery, gender, ambulatory status, hydronephrosis, degree of trabeculation, detrusor overactivity, DLPP and eventual outcome. The incidence of VUR was higher in group 1 patients ($P = 0.009$) and more patients in group 2 had an open bladder neck ($P = 0.031$).

CONCLUSION: Severe bladder trabeculation in incontinent patients with NB might predict an element of intrinsic outlet resistance. In this subset of patients, dryness was achieved by AC alone without further BOP. The degree of bladder trabeculation should be considered in the surgical decision-making process for incontinent children with NB.

DISTAL HYPOSPADIAS REPAIR WITH OR WITHOUT FORESKIN RECONSTRUCTION: A SINGLE SURGEON EXPERIENCE

Suoub M, Dave S, El-Hout Y, Braga LH, Farhat WA

OBJECTIVE: Dartos flap coverage is routinely used as a protective layer during tubularized incised plate urethroplasty (TIPU) except when an associated foreskin reconstruction (FSR) precludes its use. In this study we compare the outcome of distal hypospadias repair with and without foreskin reconstruction by the same surgeon.

MATERIALS AND METHODS: Between September 2002 and June 2007, 215 children with distal hypospadias underwent stented TIPU by a single surgeon. Of these, 25 (glanular 8, coronal 17) underwent a two-layer FSR without dartos flap coverage. An age- and time-matched group of 49 patients (glanular 10, coronal 39) who underwent TIPU with dartos flap coverage without foreskin reconstruction (NoFSR) were selected for comparison. Operative time and complications were recorded.

RESULTS: There was no significant difference in severity of hypospadias and follow-up duration (mean 17 vs 19 months, $P=0.57$) between the two groups. Operative time ranged between 30 and 86min (mean 57) in the FSR group and 35 and 113min (mean 75) in the NoFSR group ($P\leq 0.01$). Initial retraction of the foreskin by the surgeon at 6–8 weeks was successful in 15; five of the six who failed initial retraction responded to steroid cream. Four (16%) children underwent redo surgery in the FSR group (urethrocutaneous fistula in three, circumcision for recalcitrant phimosis in one). In the NoFSR group, six (12.2%) underwent redo surgery (urethrocutaneous fistula in four, removal of redundant skin in two). There was no significant difference in the need for redo surgery ($P=0.45$) or incidence of fistula ($P=0.43$) between the groups.

CONCLUSIONS: There was no statistical difference in outcome between the two techniques, particularly regarding fistula complication. The complication particular to FSR, namely initial failure of foreskin retraction, responds adequately to steroid cream application. Foreskin reconstruction is a surgical alternative in selected patients, particularly those with distal hypospadias and a personal preference of no circumcision. Larger prospective studies are needed to ascertain similarity in outcome between FSR urethroplasty and the conventional urethroplasty with dartos coverage.

LITERATURE REVIEW OF THE USE OF TUBULARIZED INCISED PLATE (TIP) URETHROPLASTY FOR DISTAL HYPOSPADIAS REPAIR

Braga LH, Lorenzo AJ, Pippi Salle JL

ABSTRACT: The tubularized incised plate (TIP) urethroplasty or Snodgrass procedure has gained worldwide acceptance for distal hypospadias repair due to its low complication rate, good cosmetic result, and technical simplicity. As a result, several articles have been published concerning various aspects and subtle variations of this procedure. The aim of this review is to critically and systematically analyze the published complication rates of TIP repair for distal hypospadias in children. We also reviewed the surgical modifications that have been introduced to the original technique and discussed the potential impact on the final outcome of the Snodgrass procedure.

WHAT IS THE ROLE OF FLAPS AND GRAFTS IN MODERN HYPOSPADIOLOGY?

Wallis CM, Braga LH, Khoury AE

ABSTRACT: The modern hypospadiologist must be proficient in the use of both vascularized flaps and free grafts. When choosing a repair for any given patient with hypospadias, one must consider the length of the urethroplasty, the presence and degree of ventral curvature and perhaps most importantly, the surgeon's own experience. Not all repairs are created equally and different complication rates and cosmetic outcomes can be seen among different surgeons utilizing the same technique. Each surgeon tends to infuse their own modifications to any given technique and many of these modifications go unreported. It is incumbent upon each surgeon to be familiar with a wide variety of techniques, which invariably includes the use of flaps and grafts. We present a spectrum of the uses of flaps and grafts in modern hypospadiology.

IS LONG TERM BLADDER DETERIORATION INEVITABLE FOLLOWING SUCCESSFUL ISOLATED BLADDER OUTLET PROCEDURES IN CHILDREN WITH NEUROPATHIC BLADDER DYSFUNCTION?

Dave S, Pippi Salle JL, Lorenzo AJ, Braga LH, Peralta-Del Valle MH, Bagli DJ, Farhat WA, Khoury AE

PURPOSE: Bladder decompensation is well described following artificial urinary sphincter implantation in neurogenic bladders. We evaluated the long-term results of various bladder outlet procedures in a subset of patients with neurogenic bladder and isolated outlet deficiency.

MATERIALS AND METHODS: We retrospectively reviewed the charts of 15 consecutive patients who underwent bladder outlet procedures during a 10-year period for urinary incontinence associated with neuropathic bladder dysfunction. Postoperative success was defined as a dry interval of at least 4 hours.

RESULTS: Preoperative evaluation showed a smooth bladder in 11 patients with vesicoureteral reflux and hydronephrosis in 2. Using the minimal acceptable capacity for age, mean percent expected bladder capacity for age was 89% +/- 25%, capacity below 20 cm H₂O was 81% and capacity below 30 cm H₂O was 89%. Mean preoperative expected capacity for age was 60% +/- 18%. Mean postoperative followup was 11.2 years. Postoperatively, 11 patients achieved initial dryness but 9 subsequently presented with recurrent incontinence and 2 presented with upper tract deterioration. Four cases failed the initial bladder outlet procedure. Salvage procedures included augmentation cystoplasty in all 15 patients, combined with repeat bladder outlet procedure in 4 and bladder neck closure in 2. Mean time to augmentation cystoplasty was 39.6 +/- 28 months.

CONCLUSIONS: Isolated bladder outlet procedures for neurogenic incontinence portend a poor long-term outcome, requiring augmentation cystoplasty despite the use of anticholinergic medications and strict followup. Preoperative urodynamic evaluation does not predict the need or timing from the initial bladder outlet procedure for future augmentation cystoplasty.

CRITICAL APPRAISAL OF THE ROLE OF URETEROSCOPY AND RETROGRADE INTRARENAL SURGERY IN THE TREATMENT OF PEDIATRIC RENAL AND URETERIC CALCULI

Dave S, Khoury AE, Braga LH, Farhat WA

INTRODUCTION: The refinement and miniaturization of ureteroscopes and ancillary instruments has led to an increased application of ureteroscopy in managing ureteric calculi in children. We report our experience with the use of ureteroscopy in managing ureteric and renal calculi and assess the results in relation to stone location and whether ureteroscopy was used as a primary or secondary treatment modality.

METHODS: A retrospective chart review was performed for 28 patients with 32 stones ranging between 2–16 years (mean 6.9 years) of age who underwent ureteroscopy for treatment of calculi between 1999 and 2004. Data collection included presentation, review of operative details, initial complete radiological clearance and follow up procedures.

RESULTS: Follow up ranged between 6–72 months (mean-23 months). Twelve of the 28 children (42%) had an associated metabolic disorder predisposing them to recurrent urolithiasis. Of the 32 stones treated, 18 were located in the upper urinary tract, 6 in the proximal ureter and 8 in the distal ureter. A postoperative ureteric stent was used in all cases. The lithotripsy modality used was the holmium: YAG laser in 25 and electrohydraulic lithotripsy in 3. Overall initial stone clearance was achieved in 85.7% (12/14) of ureteric stones. Stones located in the renal pelvis showed a 53% (7/13) clearance with poor results in those with calyceal extension. Only 1 of the 5 staghorn calculi was cleared with ureteroscopy. The 2 complications in this series were a distal ureteric perforation in 1 and a malpositioned stent with a urinoma in 1.

CONCLUSIONS: Ureteroscopy and laser lithotripsy achieves good results with minimal complications in treating ureteric calculi and stones located in the renal pelvis. The initial stone clearance achieved in large staghorn calculi or pelvic stones with calyceal extension is poor. Despite the technical challenges and the results in this group of patients it may have a limited role as salvage therapy in children with metabolic disorders who often have large stone burden and recurrent calculi.

FAILED PYELOPLASTY IN CHILDREN: COMPARATIVE ANALYSIS OF RETROGRADE ENDOPYELOTOMY VS. RE-DO PYELOPLASTY

Braga, LH, Pippi Salle, JL, Dave, S, Skeldon, S, Lorenzo, AJ, Khoury, AE, Bagli, DJ, Farhat, WA

PURPOSE: We compared retrograde endopyelotomy to redo pyeloplasty for the treatment of failed pyeloplasty in children.

MATERIALS AND METHODS: Of 32 patients with recurrent ureteropelvic junction obstruction retrograde endopyelotomy was performed in 18 and redo pyeloplasty was performed in 14. Patient age, gender, side, stent placement at initial pyeloplasty, presentation of secondary ureteropelvic junction obstruction, hospital stay, complications and success rates were compared. Success was defined as radiographic relief of obstruction as determined by ultrasound or diuretic renography at latest followup.

RESULTS: Median patient age was 6 years (range 2 to 14) at retrograde endopyelotomy and 7.2 years (1 to 17) at redo pyeloplasty. Retrograde endopyelotomy technique consisted of holmium laser in 10 patients and cautery/balloon dilation in 8. Redo pyeloplasty was performed through a flank incision in 12 patients and by laparoscopy in 2. Retrograde endopyelotomy was successful in 39% of the patients, while redo pyeloplasty had a 100% success rate ($p = 0.002$). Of the patients with failed retrograde endopyelotomy 5 had a stricture greater than 1 cm and 7 were younger than 4 years. Mean length of the narrowed ureteral segment was 10.1 mm in the failed retrograde endopyelotomy group vs 5.8 mm in the successful group ($p < 0.01$). Only 1 of 8 children (13%) had a successful retrograde endopyelotomy using cautery followed by balloon dilation. Hospital stay was 1.3 days for the retrograde endopyelotomy group and 2.9 days for the redo pyeloplasty group ($p < 0.01$). Mean followup was 47 months (range 15 to 132) after retrograde endopyelotomy and 33.1 months (12 to 78) after redo pyeloplasty.

CONCLUSIONS: Retrograde endopyelotomy had a significantly lower success rate than redo pyeloplasty for correction of recurrent ureteropelvic junction obstruction after failed pyeloplasty in children. Patient age less than 4 years and narrowed ureteral segment greater than 10 mm were associated with a poor outcome after retrograde endopyelotomy.

OUTCOME ANALYSIS OF ISOLATED EPISPADIAS IN MALES: SINGLE CENTER EXPERIENCE WITH 33 CASES

Braga LH, Lorenzo A, Dave S, Cerveira J, Khoury AE, Bagli DJ, Pippi Salle JL

PURPOSE: We review our results with isolated male epispadias repair, comparing the Cantwell-Ransley and Mitchell-Bagli procedures in regard to continence status and postoperative complications.

MATERIALS AND METHODS: We reviewed the charts of 33 patients presenting with isolated epispadias (glanular in 3, penile in 9, penopubic in 21) between 1994 and 2005. Of the 21 patients with penopubic epispadias Cantwell-Ransley repair was performed in 14 and Mitchell-Bagli repair was done in 7.

RESULTS: Mean patient age at epispadias repair was 16.8 months (range 12 to 24) and 19.3 months (9 to 42) for the Cantwell-Ransley and Mitchell-Bagli operations, respectively. After epispadias repair in the Mitchell-Bagli group 4 of 6 patients (67%) became continent vs 0 of 13 in the Cantwell-Ransley group ($p < 0.01$). Bladder neck repair was performed in 11 of 13 children (85%) who underwent a Cantwell-Ransley repair. Of these 11 boys 6 became continent. Hence, 3 of the 5 patients who failed the first bladder neck repair underwent a second bladder neck repair with augmentation cystoplasty to achieve dryness (dry more than 4 hours). The other 2 patients are on clean intermittent catheterization and have 2 to 4-hour dry intervals. After undergoing a Mitchell-Bagli epispadias repair 2 patients (33%) remained incontinent and went on to receive endoscopic injection of bulking agent to become dry. Mean followup was 70 months (range 10 to 120) for Mitchell-Bagli repair and 80 months (21 to 144) for Cantwell-Ransley repair. At last followup 13 of 17 children (76%) with penopubic epispadias were completely dry or had dry intervals greater than 4 hours. Among the 21 patients 10 (48%) had complications, of whom 8 were in the Cantwell-Ransley group (57%) and 2 were in the Mitchell-Bagli group (29%).

CONCLUSIONS: Similar urinary continence rates can be achieved for male penopubic epispadias with both surgical techniques, at the expense of more bladder neck repairs following the Cantwell-Ransley procedure.

COMPARATIVE ANALYSIS OF 3 DIFFERENT APPROACHES FOR PEDIATRIC PYELOPLASTY

Braga LH, Lorenzo AJ, Madhi M, Bagli DJ, Pippi Salle JL, Khoury AE, Farhat WA

PURPOSE: Anderson Heynes dismembered pyeloplasty is the technique of choice for correction of ureteropelvic junction obstruction (UPJO) in children. The selection of surgical access is mostly driven by surgeon preference and can be performed laparoscopically, through a flank incision, or through a dorsal lumbotomy. A comparative analysis involving these 3 different approaches has not been previously reported.

MATERIAL AND METHODS: A retrospective chart review was conducted for all patients who underwent pyeloplasty between Jan 2005 and Aug 2007. Of 53 laparoscopic pyeloplasties, we selected 29 performed by a single surgeon and compared them to 54 age matched cases who had an open approach (32 flank and 22 dorsal lumbotomy). Age at surgery, operative time, hospital stay, complication and failure rates were evaluated. Statistical analysis was performed using one-way ANOVA test.

RESULTS: The main RESULTS are displayed in the table below:

Variables	Lap *(n=29)	Flank (n=32)	Dorsal (n=22)	P (Anova)
Age (years)	7.9	8.0	7.2	0.49
Operative time (min)	187.8	163.9	167.7	0.02
Hospital stay (days)	2.3	3.6	3.3	<0.001
Complications (%)	3 (10.3)	1(3.1)	1(4.5)	0.39
Failure/Redo(%)	1 (3.4)	1 (3.1)	0 (0)	0.67
Follow-up (months)	13.5	24.9	22.6	-

*Mean op. time for the last 10 laparoscopic cases was 155 min (shorter than open operative time).

CONCLUSIONS: Although mean operative time was greater for the laparoscopic group versus open cases, mean hospital stay was significantly shorter. Laparoscopic surgical time gradually improved over time, reaching those of flank and dorsal lumbotomy patients. Overall, the success rate was similar for the 3 pyeloplasty approaches. Our data do not favour one particular surgical access over the others. Future studies on cosmesis and pain control may reveal more divergent outcomes for these 3 approaches.

SHOULD WE STILL USE ONLAY ISLAND FLAP REPAIRS FOR PROXIMAL HYPOSPADIAS?

Braga LH, Lorenzo AJ, Bagli DJ, Farhat W, Pippi Salle JL, Khoury AE

INTRODUCTION AND OBJECTIVE: There has been recent trend to favor either 2-stage repair or 1-stage TIP technique for proximal hypospadias due to their relative simplicity and perceived improved cosmesis. One-stage Onlay Island Flap (OIF) repair is considered to be more technically demanding and associated with a higher complication rate when compared to the other 2 procedures. We sought to review our experience with 1-stage OIF repair for treatment of proximal hypospadias to critically reassess our current practice.

METHODS: We retrospectively reviewed the charts of 83 consecutive boys with penoscrotal hypospadias who underwent OIF from 1996-2004. Redo and perineal cases were excluded. Eighteen pts (21.7%) had proximal penile, 60 (72.3%) penoscrotal and 5 (6%) scrotal defects. Penoscrotal transposition (PST) was present in 40 (42.2%) cases. Preoperative testosterone was used in 27/83 (35.2%) pts. Age at surgery, degree of ventral curvature (VC), length of harvested flap, complications and overall number of procedures were recorded. Comparative and descriptive analyses were reported.

RESULTS: Mean age at surgery was 18.5m (8-145) and mean followup was 33.9m (12-93m). Of 83 boys, severe VC ($>45^\circ$) was found in 35 (42.2%). The length of the flap >4 cm in 73/83 children. Complications occurred in 31/83 (37.3%) pts: fistula (14), dehiscence/breakdown (5), urethral stricture (1), diverticulum (1) and recurrent VC (2 severe, 8 mild/moderate). Six of 10 pts underwent surgical revision for correction of recurrent VC. All children with scrotal hypospadias developed complic. (3 recurrent VC and 2 fistulas) compared to 26 of 78 with proximal penile or penoscrotal (100% vs. 33.3%, $p=0.01$). Overall, 77/83 (93%) pts underwent 2 procedures (initial operation + 1 to treat the complic.), 4 (5%) 3 procedures (initial repair + 2 to fix complic.), and 2 (2%) boys needed 4 operations (initial procedure + 3 to treat complic.). Most children with fistulas needed 1 operation to correct their complic. Of the 4 pts who underwent 3 operations, 2 had dehiscence of the urethroplasty and 1 urethral stricture. Both boys who underwent 4 procedures had Balanitis Xerotica Obliterans. They were treated initially with redo lateralized OIF technique which also failed and subsequently with 2-stage buccal mucosa graft repair.

CONCLUSIONS: OIF technique was associated with a significantly higher complication rate when used for scrotal defects. Nevertheless, 90% of pts were successfully treated with a maximum of 2 procedures. OIF remains a good option for proximal penile and penoscrotal hypospadias repair.

SERIAL IMAGING STUDIES AFTER RENAL TRAUMA IN CHILDREN - IS ULTRASOUND ENOUGH?

Eeg K, Halachmi S, Braga LH, Farhat WA, Bagli DJ, Pippi Salle JL, Khoury AE, Lorenzo AJ

INTRODUCTION AND OBJECTIVE: After renal injury, which is usually detected and graded by computerized tomography (CT) scan, most admitted patients will undergo radiological re-evaluation with either a repeat CT scan or ultrasound (US). The former imaging study is frequently favored at the expense of exposure to ionizing radiation, which has been associated with possible future increased risk of malignancy. The ALARA (As Low As Reasonable Achievable) concept attempts to strike a balance between such risk and the added information obtained by exposure to radiation. At our institution the use of US has been adopted as the follow-up imaging technique of choice, with selective evaluation with CT scan. This retrospective study aims to evaluate the value of this practice in acute post-renal trauma re-evaluation.

METHODS: A retrospective analysis of a large pediatric referral center trauma database was carried out, extracting data for patients managed between 1997 and 2007. A total of 73 children with renal trauma were identified and reviewed. Associated injuries, mechanism of trauma, management, imaging studies obtained during hospital stay, complications and delayed/missed injuries were analyzed.

RESULTS: Mean age at time of injury was 10.4 years, with a 3:2 male/female ratio. In all patients the mechanism was blunt injury. Average grade of injury on admission (by CT scan) was 2.4, high grade (IV or V) in 32%. Associated injuries were detected in 67%. A repeat CT scan was obtained in 11 patients, in 81% of cases for management of non-urolologic injuries. Two patients had repeat CT scan for evaluation prior to renal embolization (1) and assessment of possible urinoma (1). Three nephrectomies were required in the setting of hemodynamic instability. Four enlarging urinomas were suspected by US and required stent or drain placement. No missed injuries or complications due to delayed diagnosis were detected in patients followed with US. At last follow-up 5 patients developed hypertension, all with an abnormal US. Patients with grade I and II injuries (n=41) did not have renal complications or missed urological injuries.

CONCLUSIONS: Our experience suggests that after initial CT scan, monitoring can be performed with US in most cases (Excluding patients with hemodynamic instability or deemed to require CT scanning for associated injuries). Selective re-evaluation with CT scan can be reserved for those with abnormalities detected on serial US, thus decreasing exposure to radiation. Application of the ALARA principle appears feasible in the setting of pediatric blunt renal trauma.

URETEROPELVIC JUNCTION OBSTRUCTION IN CHILDREN: TWO VARIANTS OF THE SAME CONGENITAL ANOMALY?

Braga LH, Liard A, Bachy B, Mitrofanoff P

OBJECTIVE: To compare the characteristics of prenatally and postnatally diagnosed ureteropelvic junction obstruction (UPJO) in children.

PATIENTS AND METHODS: We reviewed the records of 74 children who underwent pyeloplasty or nephrectomy for UPJO between 1995 and 2000. The patients were divided into 2 groups: prenatally and postnatally diagnosed UPJO. In each group, we compared age at surgery, gender, affected side, anteroposterior diameter (APD) of the renal pelvis, surgical findings, and renal function as determined by creatinine clearance.

RESULTS: Of the 74 children, 44 (59.4%) had a prenatal diagnosis of UPJO and 30 (40.6%) had a postnatal diagnosis despite the fact that all had had a fetal ultrasonography. Median age at the time of surgery was 6.3 years (4 months to 16 years) for children with postnatal UPJO and 3.6 months (1 month to 4 years) for the prenatal group. Forty-three percent of the children in the postnatal group and 25% in the prenatal group were females. Clinical manifestations in children with postnatal UPJO included abdominal pain in 13 (43%) patients, pyelonephritis in 7 (23%), urinary tract infection in 5 (16.6%), and occasional findings upon ultrasound in 5 (16.6%). Excretory urography suggested obstruction in most children. The surgical findings included ureteral kinks due to adhesions in 93.3% of postnatally diagnosed UPJO cases and in 27.3% of prenatal cases ($p < 0.01$). A reduction in mean creatinine clearance of hydronephrotic kidneys was observed for both groups when compared to reference values for the respective ages, but this difference was not statistically significant.

CONCLUSIONS: Postnatally diagnosed UPJO may be considered, at least in part, an entity different from prenatally detected obstruction due to its peculiar characteristics, i.e., postnatal UPJO more frequently affects females, manifests later in life with urinary infection or abdominal pain, and is frequently associated with ureteral kinking.

COMPARATIVE ANALYSIS OF VENTRAL PENILE LENGTHENING VS. DORSAL PPLICATION FOR SEVERE VENTRAL CURVATURE: SINGLE CENTER EXPERIENCE WITH 100 CASES

Braga LH, Bagli DJ, Pippi Salle JL, Lorenzo AJ, Dave S, Farhat WA, Khoury AE

BACKGROUND: Corporal disproportion (with a shorter ventral surface) is often the intrinsic cause of severe ventral curvature (sVC) ($> 45^\circ$) once all other intraoperative manoeuvres have been exhausted. The 2 main approaches to correct the persisting sVC are dorsal plication (DP) of the corpora or ventral corporal lengthening by tunica albuginea patching. Controversy persists as neither technique has been proven to be superior to the other with respect to initial or long-term outcome. However, a direct comparison of outcome of these 2 procedures has not been previously reported.

METHODS: A retrospective review of 100 consecutive patients who underwent repair of penoscrotal or more proximal defects from 1996 to 2004 was performed. Children were divided into 2 groups: 32 had a ventral penile lengthening (VPL) procedure and 68 dorsal plication (DP-Nesbitt). Meatal location, penoscrotal transposition, preoperative testosterone stimulation, sVC ($> 45^\circ$) at the beginning of operation and after degloving, and recurrent VC were compared between the 2 groups. Recurrent VC was assessed by direct history (children's or parents' reports) and observation in follow-up examination as documented in patients charts.

RESULTS: Mean age was 17 months (9–56) for VPL patients and 17.8 months(10–58) for DP boys. Mean follow-up was 65 months (29–120) and 62 months (30–116), respectively.

CONCLUSIONS: Although VPL-patients had higher proportion of scrotal/perineal defects and preoperative sVC, and despite showing less intraoperative improvement following degloving (v. the DP-patients), they developed significantly less postoperative recurrent VC. We therefore recommend VPL over DP for patients with sVC.

PROSPECTIVE EVALUATION OF FEMINIZING GENITOPLASTY USING PARTIAL UROGENITAL SINUS MOBILIZATION FOR CONGENITAL ADRENAL HYPERPLASIA

Braga LH, Lorenzo A, Tatsuo E, Silva L, Pippi Salle J

PURPOSE: We present our experience with partial urogenital sinus mobilization in girls with congenital adrenal hyperplasia, with particular attention to vaginal caliber, introitus position, urinary continence and genital appearance.

MATERIALS AND METHODS: We present data on a prospective evaluation of 24 girls with congenital adrenal hyperplasia who underwent feminizing genitoplasty using urogenital sinus mobilization with preservation of the pubourethral ligaments during a 4-year period. Urogenital sinus length determined by cystoscopy and degree of external genitalia virilization, defined according to Prader classification, were evaluated before reconstruction. At followup patients were examined while under sedation for evaluation of overall external genitalia cosmesis and calibration of the vagina. Urinary continence status and voiding efficiency were assessed clinically in toilet trained patients by voiding diary, and measurement of bladder capacity and post-void residual by ultrasound.

RESULTS: Patient age at operation ranged from 1 to 16 years (median 28.5 months), with a mean followup of 25 months (8 to 47). Degree of virilization was Prader type III in 3 children (12.5%), type IV in 16 (66.7%) and type V in 5 (20.8%). Urogenital sinus length was 2.5 cm or less in 17 children. Cosmetic results were good in 21 patients (87.5%) and satisfactory in 3 (12.5%). The vaginal and urethral openings were separate and identified at the surface of the vestibule in 21 girls. Adequate caliber of the mobilized vagina was achieved in 23 patients (95.8%). None of the 20 toilet trained children had urinary incontinence or recurrent urinary tract infections, with normal bladder emptying in 18 and small post-void residual in 2 (10%).

CONCLUSIONS: Urinary continence and excellent cosmetic appearance with adequate exteriorization of the vaginal and urethral openings can be achieved in most children with urogenital sinus anomaly treated with partial urogenital sinus mobilization.

SIGNIFICANCE OF MEATAL POSITION IN PROXIMAL HYPOSPADIAS: A MULTIVARIABLE ANALYSIS OF FACTORS ASSOCIATED WITH COMPLICATIONS AFTER TRANSVERSE ISLAND FLAP (TVIF) REPAIR IN 137 PATIENTS

Braga LH, Eeg K, Lorenzo AJ, Salle JL, Farhat WA, Khoury AE, Bagli DJ

BACKGROUND: Historically, proximal hypospadias has been considered a single defect without precise regard for initial meatal position. It has been reported that division of the urethral plate (i.e., onlay v. tube urethroplasty) and severe ventral curvature (sVC) are associated with higher complication rate. We sought to determine the risk factors for complications after TVIF repair in children with proximal hypospadias in order to establish the most important determinants of outcome.

METHODS: We retrospectively reviewed the charts of 137 boys who underwent TVIF repair and sVC correction from 1998 to 2005. Of these, 108 (78.8%) had preoperative proximal penile/penoscrotal and 29 (21.2%) scrotal/perineal hypospadias. Associated anomalies (AA) included > 1 of: uni/bilateral cryptorchidism (17/7), bifid scrotum (83), and ambiguous genitalia (22). Preoperative testosterone (pT) was used in 51/137 patients. Univariate and multivariable analyses of the data were performed.

RESULTS: Mean age at surgery was 19.4 months (9–40); mean follow up was 61 months (10–104). Of 137 boys, 91 (66.4%) underwent onlay and 46 (33.6%) tube (i.e., urethral plate divided) repairs. sVC (> 45°) was found in 85 (62%) cases. Children with scrotal/perineal defects received pT more often than those with proximal penile/penoscrotal cases (72.4% v. 27.2%, $p < 0.01$). Complications occurred in 64/137 (46.7%) patients: fistula (26), dehiscence/breakdown (9), stricture (3), meatal stenosis (2), diverticulum (1) and recurrent VC (23). Although onlay was associated with more recurrent VC, and tube TVIF repair with more fistulas, the overall complication rate was similar for both techniques. Thus, when assessed by univariate analysis, pT and tube urethroplasty had no impact on outcome while proximal meatal position ($p = 0.02$), sVC ($p = 0.05$) and AA ($p = 0.04$) were associated with a higher overall complication rate. However, by multivariable analysis, only the preoperative meatal location was found to be associated with complication after TVIF repair ($p = 0.038$).

CONCLUSIONS: In a multivariable analysis, the complication rate after TVIF repair for proximal hypospadias was significantly associated with meatal location only. When adjusted for the initial position of the meatus, variables previously felt to be clinically relevant — the type of urethroplasty, the decision to use pT or not, or sVC — were not found to be statistically associated with overall complications. Thus, initial meatal position may be a marker of an underlying penile anatomy predisposed to more complex healing and complications.

INITIAL VALIDATION OF A NOVEL INANIMATE BENCH-TOP TEACHING MODEL FOR LAPAROSCOPIC RECONSTRUCTIVE PROCEDURES

Dubrowski A, Brydges R, El-Hout Y, Braga LH, Lorenzo A, Farhat WA

INTRODUCTION AND OBJECTIVE: Although laparoscopic approach is increasingly adopted, common urologic reconstructive procedures are still challenging by laparoscopy with a steep learning curve. We introduce a novel inanimate bench-top model suitable to simulate pyeloplasty/ureteral reimplantation and evaluate performance on this model. The purpose of this study was to demonstrate the effectiveness of the model and to correlate performance on it to that on the previously validated Fundamentals of Laparoscopic Surgery (FLS) assessment modules.

METHODS: The model was assembled by putting a ping-pong ball inside a latex balloon with food colorant fluid simulating a kidney or bladder, then placed inside a second balloon containing mineral oil, mimicking a renal pelvis or urinary bladder mucosa. A penrose drain was used as a ureter that could be spatulated and sutured to the “outer balloon” after an incision is cut into it. The mineral oil allowed easy handling of the outer balloon without violation of the inner balloon, where an erroneous move spills colored fluid. Eighteen pediatric urology fellows were asked to complete FLS assessment modules and perform anastomosis on this model (for 20-mins) before and after a 3-day intensive lab-based course. The pre and post-course sutures number and quality were inspected independently by two laparoscopists. The pre and post course model assessment scores and FLS scores were compared using two, 2-tail Student's t-tests. Individual scores for this model and FLS were also correlated using Pearson correlation method.

RESULTS: The inter-rater reliability was assessed at 0.75 suggesting a good agreement between the two evaluators. The suture line in the anastomosis of the model showed improvement in suture quality due to practice (pre-test= 1.83, post-test=2.35, $p < 0.05$). The FLS scores also showed similar improvements (pre-test=160, post-test=250, $p < 0.001$). There was a significant correlation between total FLS score and the assessment of suture quality (Pearson correlation=0.32, $p < 0.05$).

CONCLUSIONS: The construct validity of this model was demonstrated, whereby performance improved from pre to post-test. This improvement was similar to improvements demonstrated with a previously validated FLS. Although further large scale validation is mandatory, the model may be a useful and inexpensive simulation tool for teaching in laparoscopic reconstructive procedures.

SINGLE-SURGEON EVOLUTION OF MANEUVERS IMPACTING FISTULA FORMATION IN TUBULARIZED INCISED PLATE HYPOSPADIAS

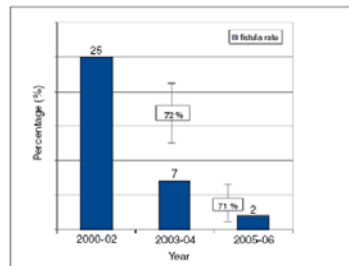
Braga L, Suoub M, Lorenzo A, El-Hout Y, Khoury A, Pippi Salle J, Bagli D

INTRODUCTION AND OBJECTIVE: To assess the impact of specific surgical maneuvers on fistula reduction during evolution of tubularized incised plate (TIP) repair for distal and midshaft hypospadias in children.

MATERIALS AND METHODS: A retrospective chart review of 220 patients who underwent TIP repair by a single surgeon between 2000 and 2006 was performed. Sixty-seven children with proximal hypospadias, redo cases and incomplete follow-up were excluded, resulting in 153 patients to form our study sample. The surgeon experience was divided into 3 periods: 1) 2000–2002; 2) 2003–2004; and 3) 2005–2006. The evolution of TIP urethroplasty was judged based on the fistula rate for each period after adjusting for stent insertion. Comparative analysis between those time periods was performed using χ^2 .

RESULTS: Mean age at surgery was 16 months (range 6–96), with a mean follow up of 9.6 months (range 1.5–60). Urethral meatus was located at the corona in 101 (66%), distal shaft in 32 (20%), midshaft in 15 (10%) and glandular in 5 (4%). Of 153 patients, 119 (77.8%) underwent repair with dartos flap coverage: 55 using double “pants over vest” and 64 using single layer. Stent was inserted in 65 (42.5%) boys. Overall, 20 children developed fistula (13%). A significant drop in fistula rate occurred from period 1 (14/55, 25%) to period 2 (5/57, 7%), ($p = 0.02$). This coincided with increase in the use of single-layer dartos coverage during period 2 over period 1 (91% v. 49%, $p = 0.04$). The fistula rate further reduced to 2% (1/41) during period 3. This fact was attributed to incorporation of double-layer dartos coverage in the majority of TIP repairs performed in period 3, compared with period 2 (71% v. 36%, $p = 0.03$).

CONCLUSION: According to this 7-year single surgeon experience, adoption of dartos flap coverage appeared to be responsible for the significant drop in fistula rate observed between periods I and II. Adding a second layer of dartos flap (double dartos coverage) may have offered further protection against leakage, helping to reduce the incidence of fistula during period 3 (Fig. 1).



IDENTIFYING AND PREDICTING CASES AT RISK FOR FISTULA FORMATION IN DISTAL HYPOSPADIAS REPAIR: IMPACT OF PROSPECTIVELY RECORDED SURGEON IMPRESSIONS

Braga L, Lorenzo A, Salle G, Pippi Salle J

INTRODUCTION AND OBJECTIVE: Urethrocutaneous fistula (UCF) is the most common complication following distal hypospadias repair. Older patient age, poor quality of the urethral plate (UP) and technical factors have been previously related to fistula formation. We sought to analyze factors associated with fistula development and assessed the surgeon's ability to predict cases at risk for complications.

MATERIALS AND METHODS: We reviewed 103 consecutive boys with distal hypospadias who underwent tubularized incised plate repair by a single surgeon over a 3-year period. Data on patient age, ventral skin deficiency (VSD), quality of the UP, ventral curvature (VC), spongioplasty, urethroplasty technique (1- v. 2-layer closure) and dartos flap coverage were retrospectively collected. Poor quality UP was defined as narrow, shallow or inelastic plate, and noted down intraoperatively by the surgeon. Fistula rate was analyzed for each variable separately. Surgeon impressions were prospectively recorded, and cases thought to be at high risk for UCF were flagged.

RESULTS: Median age at surgery was 12 months (7–204 mo). Spongioplasty was carried out in all children. Overall fistula rate was 5.8% (6/103) after a mean follow-up of 13 months (6–30 mo). Of the 6 UCFs, 3 occurred in patients older than 46 months (1 also had poor UP) and 3 in boys with no dartos coverage (1 also had poor UP). The operating surgeon correctly predicted 5 of 6 UCFs (3 with no dartos and 2 with poor UP). The positive and negative predictive values for surgeon impression were 83% and 99% respectively (Table 1).

CONCLUSION: Age > 18 months and absence of neourethra coverage with dartos flap were associated with a higher fistula rate. In this series, poor UP and 2-layer urethroplasty did not seem to affect hypospadias outcome. An experienced surgeon may accurately predict most fistula cases and precisely anticipate a favourable outcome.

Abstract 15. Table 1.

Variables	Fistula rate		p value
	n = 6/103	%	
Age > 18 months	4/27	14.8	0.02
Age < 18 months	2/76	2.6	
2-layer urethroplasty	0/26	0	0.14
1-layer urethroplasty	6/77	7.8	
Poor UP	2/18	11.1	0.29
Good UP	4/85	4.7	
Absence of dartos coverage	3/3	100	< 0.01
Dartos flap coverage	3/100	3.0	
	Final outcome		
Surgeon impression	Fistula	No fistula	Total
at risk for fistula	5	1	6
not at risk for fistula	1	96	97

SELECTIVE ABLATION OF INTESTINAL MUCOSA USING LASER PHOTODYNAMIC THERAPY WITH 5-AMINOLAEVULINIC ACID: AN EXPERIMENTAL STUDY IN PIGS

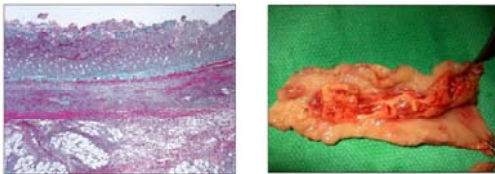
Braga L, Gartner M, Majhi M, Khoury A, Lorenzo A

INTRODUCTION AND OBJECTIVE: Photodynamic therapy (PDT) involves photosensitizing tissue with 5-aminolaevulinic acid (ALA) and then activating it with monochromatic light (laser), causing necrosis. Precise control of the extent of injury should be possible by varying the energy density of the light applied to the target issue.

MATERIALS AND METHODS: We tested the sensitivity of the bowel to PDT by instilling a 2% solution of ALA into a 20-cm isolated ileal segment of 3 female pigs. After 4 hours, the ileum was opened and cleansed. A 2-cm² circle of mucosa was exposed to predetermined 45 mW of light produced by an argon-pumped dye laser. Four 2-cm² circles of ileal segment of the first 2 pigs were exposed to energy densities of 10, 25, 50 and 100 J/cm², controlled by 2.6, 6.5, 13 and 26 minutes of laser exposure times, respectively. After 48 hours, the pigs were euthanized and the bowel segments were fixed, sectioned and stained. Histological staining techniques, including H&E and Masson's trichrome, were performed to show the extent of bowel injury. In the third pig, we limited the light dose based on our previous histological findings in order to determine the correct dose responsible for selective mucosal ablation.

RESULTS: Four distinct circles with different degrees of intestinal injury were identified on the ileal segment gross section of the first 2 pigs. Microscopically, the extent of injury ranged from mucosal necrosis alone to full intestinal wall damage (all 4 layers) without perforation. Four different circles (3–6 min laser exposure time) were also seen in the third pig's ileal segment, which was exposed to light doses ranging from 10 to 20 J/cm². Microscopically, the extent of injury ranged from mucosal to submucosal injury (Fig. 1). By adjusting the time exposure in the third pig, 15 J/cm² of PDT enabled mucosal ablation without damaging the submucosa (Fig. 2). Similar results were obtained when the experiment was repeated in a different ileal segment of the same pig.

CONCLUSION: Based on our preliminary results, PDT with 2% ALA and laser exposure of 15 J/cm² appears to be safe and effective to selectively ablate ileal epithelium in pigs.



OUTCOME ANALYSIS OF PERITONEAL DIALYSIS CATHETER PLACEMENT IN CHILDREN: IMPACT OF MALFUNCTION AND NEED FOR SURGICAL REVISION

El-Hout Y, Farhat W, Braga L, Assal A, Pippi Salle J, Khoury A, Harvey E, Lorenzo A

INTRODUCTION AND OBJECTIVE: Peritoneal dialysis (PD) is the preferred method of renal replacement therapy for children with renal failure awaiting renal transplantation or recovering from an acute insult. Despite strict adherence to details, complications requiring surgical intervention are relatively common. In this study, we sought to analyze the effect of revisions on long-term PD success.

MATERIALS AND METHODS: A retrospective analysis of a single center experience with 89 consecutive children started on PD between 1996 and 2006 was conducted. Patient demographics, indication for PD, time to initiate dialysis, complications, catheter removal or repositioning and the need for conversion to hemodialysis (HD) were recorded. Variables were subjected to univariable time-to-event and Cox analysis. Patients were censored at time of renal function recovery, renal transplantation, last follow-up or death.

RESULTS: Mean age at insertion was 83 months. Thirty-four children were temporarily placed on PD while recovering from acute renal failure. On average, patients were on PD for 9.2 months (range 0.03–56 mo). Catheter-related complications were reported in 36, most commonly infection and malfunction. Revisions were carried out in 12 patients (range 1–7 procedures). Infection had a significant effect on need to transfer from PD to HD ($p = 0.02$), even while correcting for other factors. Surgical revision did not affect the long-term success of PD. Laparoscopic exploration allowed for early dialysis resumption with no increased risk of fluid leak.

CONCLUSION: Catheter displacement or malfunction can be surgically addressed without affecting the overall success of PD, even after multiple procedures. Laparoscopic revision is feasible and allows early resumption of dialysis. Prevention of catheter related infections is likely to minimize the need to transfer to HD.

A MATHEMATICAL MODEL TO PREDICT PENILE SHORTENING AFTER DORSAL PPLICATION IN HYPOSPADIAS REPAIR

El-Hout Y, Pippi Salle J, **Braga L**, Bagli D, Khoury A, Lorenzo A

INTRODUCTION AND OBJECTIVE: Ventral curvature is a defined component of hypospadias anomaly. Among corrective surgical techniques dorsal placcation (DP) is favoured by many, especially for mild–moderate curvature. However, anticipated penile shortening (PS) may discourage surgeons from employing DP, particularly in patients with moderate–severe curvature or small penises. No previous studies have looked into prediction of the PS degree after DP. Herein, we propose a nomogram based on a mathematical model to predict PS after DP and verify its validity on a prospective single-centre pediatric cohort.

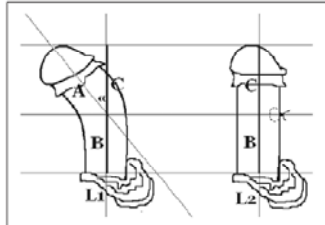


Fig. 1. Derivation of formula shortening $\Delta(\text{delta})L = L1 - L2 = A [1 - \cos \alpha(\text{alpha})]$ where A is length from glans to point of maximal curvature and $\alpha(\text{alpha})$ is chord's angle.

MATERIALS AND METHODS: Over a 6-month period, 100 consecutive patients undergoing hypospadias repair were enrolled. Intraoperative data, including digital photography with erection tests, was recorded. DP was performed based on surgeon preference. Following trigonometry principles a model to calculate PS was formulated (Fig. 1). Measured PS, (L1-L2) utilizing pre- and post-DP photographs, and calculated PS, utilizing the proposed formula, were compared.

RESULTS: Erection test was done on 82 patients. Of those, 38 had straight erections, 27 had mild curvature improving on degloving and 17 had further straightening techniques (13 DP, 2 ventral lengthening and 2 fairy cuts). Measurement was technically possible in 7 patients undergoing DP. Measured and calculated PS values were highly correlated in linear regression analysis (Pearson coefficient = 0.992, $p < 0.01$). A penile shortening nomogram was constructed (Fig. 2).

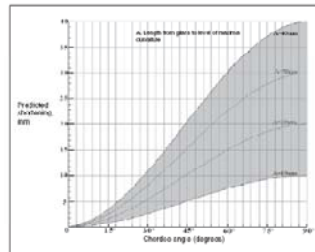


Fig. 2. Penile shortening nomogram.

CONCLUSION: This mathematical model provides a predictive nomogram for PS after DP. Shortening appears to rely on degree of curvature and the penile length. With further validation the model has potential clinical applicability.

OUTCOME ANALYSIS OF DIFFERENT PYELOPLASTY APPROACHES IN AN AGE MATCHED PEDIATRIC COHORT

Braga L, Lorenzo A, Majhi M, Bagli D, Khoury A, Farhat W

INTRODUCTION AND OBJECTIVE: Anderson-Hynes dismembered pyeloplasty is the technique of choice for correction of ureteropelvic junction obstruction (UPJO) in children. The selection of surgical approach is mostly driven by surgeon preference, including laparoscopy, flank incision, or dorsal lumbotomy. An outcome analysis involving these 3 different approaches has not been previously reported.

MATERIALS AND METHODS: A retrospective chart review was conducted for all patients who underwent laparoscopic pyeloplasty between January 2005 and July 2007. Of 53 laparoscopic cases (lap), we selected 29 performed by a single surgeon and compared them to 54 age-matched patients out of 203 who had an open approach between 2003 and 2007 (32 flank and 22 dorsal lumbotomy). Children younger than 3 years were excluded to allow age-matched comparison to the laparoscopic group. Age at surgery, operative time, performance of retrograde pyelogram (RPG), hospital stay, and complication/failure rates were evaluated. Statistical analysis was carried out using one-way ANOVA.

RESULTS: See Table 1.

CONCLUSION: Although mean operative time was greater for the laparoscopic group versus open cases, mean hospital stay was significantly shorter. Overall, the success rate was similar for the 3 pyeloplasty approaches. Although the 3 groups had different follow-up periods, our data do not favour one particular surgical access over the others. Future studies on cosmesis and pain control may reveal more divergent outcomes for these 3 approaches.

Table 1. Abstract 3.

Variable	Laparo- scopic* n = 29	Flank: n = 32	Dorsal: n = 22	p value; ANOVA
Mean age, yr	7.9	8.0	7.2	0.49
Mean operative time, min	187.8	163.9	167.7	0.32
RPG, %	12 (41.4)	21 (65.6)	10 (45.5)	0.33
Mean hospital stay, d	2.3	3.6	3.3	0.011
Complications, %	3 (10.3)	1 (3.1)	1 (4.5)	0.39
Failure/re-do, %	1 (3.4)	1 (3.1)	0 (0)	0.57
Mean follow-up, mo	13.5	36.9	34.3	0.011

*Mean operative time for the last 10 laparoscopic cases was 150 minutes (similar to open, see Fig. 1). Complications included readmission for postoperative GI bleed (1/29), prolonged urinary leakage from Penrose (2/29) and stent misplacement in the uretra (1/29 - dorsal lumbotomy). One failure occurred in a non-RPG flank incision pyeloplasty and 1 after a RPG-laparoscopic case.
†Kruskal-Wallis test was used for nonparametric data.

